Unusual intra-rectal "laterally spreading tumour" in immunosuppressed patient with ulcerative colitis

S. Vieujean[1], P. Latour[1], C. Coimbra[2], P. Delvenne[3], E. Louis[1], C. Van Kemseke[1]

(1) Department of Gastroenterology, Liege, Belgium ; (2) Department of Abdominal Surgery, Liege, Belgium ; (3) Department of Anatomopathology Liège, Belgium.

Abstract

Condyloma acuminatum (CA) is a manifestation of Human Papillomavirus (HPV) infection which usually occurs in genital and perianal regions. We report a 46-year-old man with an ulcerative proctitis diagnosed four years earlier, asymptomatic for a long time under azathioprine but without any follow-up for three years. A colonoscopy was performed prior to potential immunosuppressive treatment discontinuation and showed a circumferential "laterally spreading tumour" in the rectum. Surprisingly biopsies revealed a CA with a very focally high-grade intra-epithelial lesion. Azathioprine was stopped and a transanal surgical resection was performed. At guided anamnesis, patient confirmed to be a former active "men who have sex with men". No recurrence of proctitis occurred despite azathioprine discontinuation. A retrospective review of the histological sections suggests that it was, in fact, an intestinal spirochetosis misdiagnosed as inflammatory bowel disease. Involvement of the rectal mucosa by HPV is a rare condition and this may have been promoted by inappropriate immunosuppressive treatment. (Acta gastroenterol. belg., **2021**, 84, **509-512**).

Keywords: Condyloma acuminatum, rectum, men who have sex with men, intestinal spirochetosis.

Introduction

Condyloma acuminatum (CA) is caused by Human Papillomavirus (HPV) infection and is one of the most common sexually transmitted disease in the world. HPV infection usually occurs in the genital or perianal regions and the involvement of the rectal mucosa is a rare condition. Among the risk factors for CA, immunosuppression can promote both the occurrence of these condyloma but also the transformation into carcinoma (1,2). We report here, the case of a patient who developed CA favoured by an immunosuppressive treatment started in a context of possibly misdiagnosed inflammatory bowel disease (IBD).

Case report

A 46-year-old man was admitted in June 2015, for the first time in our department, for a colonoscopy in a context of ulcerative colitis, diagnosed 4 years earlier. When diagnosed, the patient had bloody diarrheas, mucus and tenesmus and the location was an ulcerative proctitis. The patient is a smoker and has only a previous history of appendectomy. At time of diagnosis, he was treated by mesalasine suppositories, oral corticoids, and budesonide enema. Five months after diagnosis, azathioprine was started (250 mg/day for a weight of 81 kg) for cortico-dependence. Patient was asymptomatic for a long time with azathioprine and no follow-up had been achieved for at least 3 years. Thus, he wanted to stop his azathioprine treatment. Prior to potential immunosuppressive treatment discontinuation, a fecal calprotectin (FC) dosage and a colonoscopy were performed.

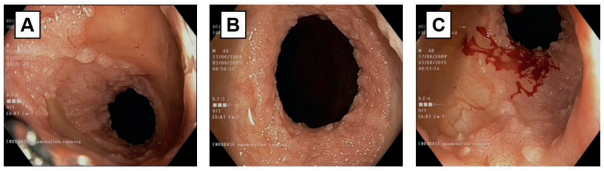

Figure 1. — Condyloma acuminatum (CA) observed by colonoscopy.

The FC rate was 90 µg/g and an unusual rectal lesion was observed at colonoscopy (Fig. 1). The lesion seems to be a circumferential « laterally spreading tumor » with villous appearance, forming an annular lesion beginning at 6-7 cm from the anal margin (AM). The lesion extended towards the pectinea line on a third of the circumference, drawing a small triangle. For the rest, the colon and terminal ileum were normal.

Surprisingly, rectal biopsies revealed a CA with a very focal high-grade intra-epithelial lesion and an overexpression of the p16 protein (cell marker induced by oncogenic HPV). The assessment performed on this patient has therefore demonstrated, besides an UC in clinical and endoscopic remission, a low rectal lesion corresponding to a CA, an unusual lesion in the rectal mucosa. A transrectal ultrasonography was performed but did not provide additional information.

Immunosuppressive therapy was stopped, and a surgical management was discussed. The circumferential nature of the lesion made endoscopic or surgical resection problematic (major risk of stenosis). The presence of very focal high-grade intra-epithelial lesions led us to a surgical management. Surgeons proposed a resection in two steps with resection of intraductal lesions and a portion of intrarectal lesion and, in a second step, the removal of the second hemi-circumference. A transanal resection was chosen. Biopsies of the surgical piece

Correspondence to : Catherine Van Kemseke, Department of Gastroenterology, CHU Liège, Avenue de l'hôpital, 1, 4000 Liège, Belgium. Fax: +3242425519; E-mail : cvankemseke@chuliege.be

Submission date : 14/06/2020
Acceptance date : 07/10/2020

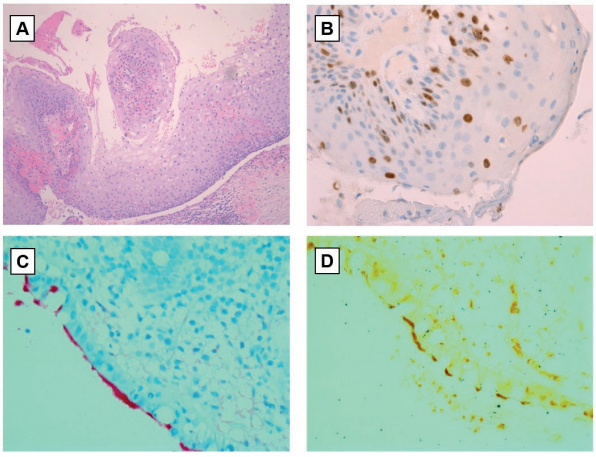

Figure 2. — A-B. Condyloma acuminatum (CA) showing typical histological features demonstrated by hematoxylin eosine staining (A) and increased epithelial proliferation by immunohistology with a Ki67 antibody (B). C-D. Human intestinal spirochetosis demonstrated by immunohistology (C) and Warthin-Starry silver staining (D).

revealed a condyloma without evident dysplasia and an HPV infection (Fig. 2A and 2B).

FC dosage and rectosigmoidoscopy were performed at 6 months and then by an annual follow-up. No recurrence of active ulcerative proctitis occurred despite azathioprine discontinuation. After a detailed anamnesis on sexual behaviour, patient confirmed to be a former active "men who have sex with men" (MSM). A retrospective review of the histological sections performed in 2011 from the endoscopy at diagnosis of UC suggest that it was, in fact, an intestinal spirochetosis misdiagnosed as inflammatory bowel disease (Fig. 2C and 2D).

Discussion

Intra-rectal condyloma acuminatum

CA is caused by HPV, a double-stranded deoxyribonucleic acid (DNA) virus, member of the Papillomaviridae family. HPV are divided into low-risk (subtypes 6 and 11) and high-risk (subtypes 16, 18 and 31) types according to the association with the development of benign or malignant lesions (3). Anal HPV infections are very common in MSM (4). This virus mainly affects the genital and perianal regions and involvement of the rectal mucosa is a rare condition. We found, in the literature, few case reports of rectal CA (5-10) (Table 1). They manifested by a rectal syndrome with a broad differential diagnosis, including especially adenoma, adenocarcinoma, mesenchymal tumours like GIST, neuroendocrine tumours, ganglioneuroma, melanoma and endometriosis in woman. A careful endoscopic examination (using high-definition endoscopy) can differentiate CA from other disorders and a biopsy may be helpful to confirm the diagnosis when uncertain.

Rectal CA may appear after direct infection from anal intercourse or can be the result of the spread of genital or perianal warts into the rectum (8) or can be transmitted via formites such as sex toys (11). CA may also be implanted on the rectal mucosa beyond the mucocutaneous junction (5). Risk factors for rectal CA are similar to those of the anogenital region: sexual activity, smoking (risk proportionally increases with the pack-years number) (12) and immunosuppression (associated with greater resistance to treatment, more recurrence and malignant transformation) (1). An additional evaluation is needed with assessment of sexual partners, research of other sexually transmitted diseases and other involvements: anal canal, urethra, vagina and cervix.

The treatment purpose is to destroy clinically visible lesions. Among available treatments, there are chemical treatments (podophyllotoxine, 5-fluorouracile, trichloracetic acid), immunomodulator treatment (imiquimod) and physical treatments based on the destruction or removal of lesions (laser, fulguration, freezing microwaves and surgery). New endoscopic techniques need to be investigated further. Although an endoscopic submucosal dissection could have been performed in this case, the presence of dysplasia guided us toward a surgical resection.

Infectious proctitis may mimic IBD

Diagnosis of infectious proctitis is frequently delayed because of the nonspecific clinical presentation, the physician's unawareness of sexual behaviour and the lack of routine diagnostic test (poor screening protocol) for this disease (13,14). When evaluating new-onset proctitis, all infectious causes must be excluded especially in the following situations: (1) when clinic, endoscopic or histologic findings are not consistent with the typical findings of IBD, (2) when additional components of sexual history emerge or for patient having risk factors (Table 2) (15), (3) when there is a response failure to IBD therapy or when antibiotics lead to a clinical improvement (14).

Early diagnosis is imperative, because patient with undiagnosed and untreated rectal STI are at risk of disease progression, onward transmission of infection and increase susceptibility to co-infection (including HIV) (11). Furthermore, a delayed diagnosis can lead to expose patients to unnecessary investigations and inappropriate treatments.

Human intestinal spirochetosis (HIS) is a condition defined histologically by the adherence of spirochetes, predominantly *Brachyspira aalborgi* and *pilosicoli*, to the apical cell membrane of the colorectal epithelium. Spirochetes are transmitted by fecal-oral route but sexual transmission has also been suggested because of its higher incidence in homosexuals, with a colonisation rate ranging from 20,6 to 62,5% according studies (16). The clinical significance of these organisms has been debated for years. A review of the literature assumes that

Table 1. — **Reported cases of rectal CA in the literature**

	Number of cases reported	Sex	Age (years)	HPV subtype	Dysplasia	Immunosuppression	Distance from AM	Sexual activity	Treatment
Chester et al. (1955)	7 cases between 8/12/1948 et 29/09/1953	M	NR	NR	NR	NR	NR	No anal intercourse	Podophyllin and electrofulguration under direct view with the sigmoidoscope.
Serra-Aracil, X. et al (2014)	1	NR	NR	NR	NR	NR	8 cm	NR	Transanal endoscopic microsurgery
Musquer et al. (2014)	1	F	43	NR	NR	NR	NR	NR	Endoscopic snare resection
Ye Y. et al. (2015)	1	F	37	HPV-6	NR	NR	5 cm	Anal intercourse	Electrocoagulation
Azzolini et al. (2015)	1	F	63	HPV-11	Low-grade dysplasia	NR	NR	Not specify	Endoscopic submucosal dissection
Ortenzi et al. (2016)	6	NR	NR	NR	NR	NR	NR	NR	Transanal endoscopic microsurgery

Only abstract in English are selected. Buschke-Loewenstein tumour are excluded as well as anal condyloma acuminatum extending into lower rectum. M : male ; F : female ; NR : not reported ; HPV : Human Papillomavirus ; AM : anal margin.

Table 2. — **Risk factors associated with sexually transmitted infections**

Risk factors associated with sexually transmitted infections (12)
Younger age (less than 25 years at higher risk)
People from or who have visited countries with higher rates of STI
Men who have sex with men
Frequent partner change or multiple concurrent partners
Early onset sexual activity
Previous STI or previous contact with STI
Alcohol or substance misuse

STI : Sexually transmitted infection.

invasion of spirochetosis beyond the surface epithelium may be associated with gastrointestinal symptoms, such as chronic mucosal diarrhea, rectal bleeding, abdominal pain and weight loss, mimicking IBD as in the present case (16,17). Individuals without any invasion are in principle asymptomatic (16), but, for unknown reason, homosexual and HIV-positive men as well as children are more likely to be symptomatic with a single colonisation (16). The treatment usually involves 5 to 10 days of metronidazole but symptomatic improvement with the use of other antibiotics (such as clindamycin or macrolides) (16) and spontaneous resolution has also been reported (18), which could explain clinical improvement of this patient without metronidazole.

Some authors are suggesting the existence of a possible relationship (overlap) between HIS and UC (17). The links between HIS and UC are close but complex with 3 possible groups: (1) UC accompanied temporally or incidentally by HIS, (2) UC associated with HIS and (3) HIS mimicking UC. Based on the fact that the patient developed a relatively refractory proctitis justifying the initiation of immunosuppressive therapy and that no recurrence was observed despite treatment removal, we concluded that proctitis was secondary to HIS and not to UC (group 3 case), and that the patient possibly contracted a HPV co-infection.

Immunosuppressant and CA

In this present case, the absence of response to IBD treatment pushed the clinician to initiate an immunosuppressor which probably favoured the occurrence of the CA. Indeed, IBD patients treated by thiopurine present a higher rate of HPV infection and CA with a higher risk of dysplasia (1). Immunosuppression allows oncogenic mutations to perpetuate with a decreased immune surveillance and apoptosis.

Conclusion

Although proctitis is most frequently associated with IBD, infectious proctitis has particularly increased in the last years, especially in men who have sex with men (MSM). As there is an overlap between clinical, endoscopic and histologic findings with IBD, IST should always be considered. Among these, HIS is frequent in homosexuals and may mimic IBD. Delayed diagnosis may lead, among other complications, to expose patients to unnecessary drug therapy, which, in this case, probably favoured the occurrence of this intra-rectal condyloma.

Conflict of interest

No conflict of interest.

References

1. KANE S., KHATIBI B., REDDY D. Higher incidence of abnormal Pap smears in women with inflammatory bowel disease. *Am. J. Gastroenterol*., 2008, **103**(3) : 631-636.
2. D'HONDT L., FILLEUL B., GUILLAUME T., HUMBLET Y., LONGUEVILLE J., WILLOCX R. *et al*. Severe anal condylomata acuminata following high-dose chemotherapy and autologous hematopoietic stem cell transplantation : A case report. *Acta Gastroenterol. Belg*., 1996, **59**(4) : 254-255.
3. HOANG P., LI L., SIBILLE C., DALTON H., MARBAIX E., KARTHEUSER A.H., *et* al. *Acta Gastroenterol. Belg*., 1996, **59**(3) : 214-216.

4. SMITH J., GILBERT P., MELENDY A., RANA R., PIMENTA J. Age-specific prevalence of human papillomavirus infection in males: a global review. *J. Adolesc. Health*, 2011, **48**(6) : 540-552.
5. CHESTER B., SCHWIMMER B. Perianal verruca acuminata with mucosal lesions. *AMA Arch. Derm*., 1955, **71**(2) : 149.
6. SERRA-ARACIL X., MORA-LOPEZ L., ALCANTARA-MORAL M., CORREDERA-CANTARIN C., GOMEZ-DIAZ C., NAVARRO-SOTO S. Atypical indications for transanal endoscopic microsurgery to avoid major surgery. *Tech. Coloproctol*., 2014, **18**(2) : 157-164.
7. MUSQUER N., BOSSARD C., CORON E. An uncommon combination of polyps. *Gastroenterology*, 2014, **147**(3) : e1-e2.
8. YE Y., Sun X., Feng J. Woman with rectal condyloma acuminatum: a case report. *Int. J. Clin. Exp. Med*., 2015, **8**(4) : 6365-6368.
9. AZZOLINI F., CECINATO P., IORI V., MARCO L., ZECCHINI R., FODERO C., *et al*. Endoscopic submucosal dissection of an unusual flat rectal neoplasm. *Gut*., 2015, **64**(1) : 180-183.
10. ORTENZI M., GHISELLI R., CAPPELLETTI TROMBETTONI M., CARDINALI L., GUERRIERI M. Transanal endoscopic microsurgery as optimal option in treatment of rare rectal lesions: a single centre experience. *World J. Gastrointest. Endosc*., 2016, **8**(17) : 623-627.
11. GROOME M., ROBINSON E., MOWAT C., MORIEUX A., ALLSTAFF S. Are patients in the IBD clinic at risk of proctitis secondary to sexually transmitted infections? *Frontline Gastroenterol*., 2017, **8**(4) : 267-271.
12. BANURA C., MIREMBE F., OREM J., MBONYE A., KASASA S., MBIDDE E. Prevalence, incidence and risk factors for anogenital warts in Sub Saharan Africa : a systematic review and meta analysis. *Infect. Agent Cancer*, 2013, **8**(1) : 27.
13. VAN KEMSEKE C. Sexually transmitted diseases and anorectum. *Acta Gastroenterol. Belg*., 2009, **72**(4) : 413-419.
14. GALLEGOS M., BRADLY D., JAKATE S., KESHAVARZIAN A. Lymphogranuloma venereum proctosigmoiditis is a mimicker of inflammatory bowel disease. *World J. Gastroenterol*., 2012, **18**(25) : 3317-3321.
15. CLUTTERBUCK D., FLOWERS P., BARBER T., WILSON H., NELSON M., HEDGE B. *et al*. UK national guideline on safer sex advice. *Int. J. Std. AIDS*, 2012, **23**(6) : 381-388.
16. TSINGANOU E., GEBBERS J. Human intestinal spirochetosis--a review. *Ger. Med. Sci*., 2010, **8** : Doc01.
17. NISHII S., HIGASHIYAMA M., OGATA S., KOMOTO S., ITO S., MIZOGUCHI A., *et al.* Human intestinal spirochetosis mimicking ulcerative colitis. *Clin. J.. Gastroenterol.*, 2018, **11**(2) : 145-149.
18. SINHA A., MAK T., PETKAR S., ALLAN A. Intestinal spirochetosis: do we always treat it or is it a self-limiting disease? *Saudi J. Gastroenterol*., 2009, **15**(2) : 139-141.